



Case Report

Angioembolization as an effective alternative for hemostasis in intractable life-threatening maxillofacial trauma hemorrhage: case study

Life-threatening maxillofacial trauma hemorrhage is not common; oronasal hemorrhage from maxillofacial trauma can often be managed with manual compression or efficient tight packing. Surgery is reserved for cases where failure of tight packing occurs. However, the use of angioembolization might decrease the need for blood transfusion and provide an effective alternative for early hemostasis after packing failure. We report 7 cases wherein angioembolization was successfully performed for hemostasis of life-threatening maxillofacial trauma hemorrhage.

Maxillofacial injuries often result in airway compromise, hemorrhage, and bony fracture [1-3]. As the popularity of restraint-equipped automobiles and airbags expanded, reports of maxillofacial injuries with airbag deployment increased [4,5]. Most hemorrhages from maxillofacial injuries can be managed with adequate nasal packing or direct pressure or even wiring of mandibular fractures [6]. However, persistent life-threatening hemorrhage is not common, the incidence rate ranges from 1.2% to 4.5% in maxillofacial injuries [1-3,6]. Nonetheless, if persistent life-threatening hemorrhage occurs, emergent life-saving surgery with open reduction and internal fixation or ligation of focal vessels (eg, internal maxillary artery, external carotid artery) might be necessary [6,7]. On the other hand, transcatheter arterial embolization (TAE) has been applied in the management of intractable posterior epistaxis and has achieved a high success rate with a low complication rate [8-10]. Therefore, it was also considered as an alternative in the management of intractable hemorrhage in life-threatening maxillofacial trauma [3,11,12].

Herein, we report 7 cases where angioembolization was successfully performed in hemostasis of life-threatening maxillofacial trauma hemorrhage.

Among 7 patients with life-threatening maxillofacial hemorrhage, we present 2 selected patients for discussion due to exemplary, vigorous hemorrhage.

The maxillofacial computed tomography (CT) scans were obtained using a GE Light Speed Scanner (GE Medical Systems, Milwaukee, Wis). Patients received 100 mL of intravenous bolus of nonionic contrast Ioversol (Optiray, Mallinckrodt Inc, Hazelwood, Mo). Ten-millimeter cuts were obtained. All CT scans were initially read by staff trauma surgeons and are later reviewed by staff

radiologists. Contrast extravasation/contrast blush is defined as a focus of high-attenuation contrast material on CT film. The angioembolization was performed by interventional radiologists. Arterial access was obtained via right femoral artery, and a 6 Fr[#] right femoral sheath was used. A 5 Fr[#] RC1 catheter (Cook, Bloomington, Indiana) was used for external carotid artery catheter. Patients underwent embolization with coils (Cook, Bloomington, Indiana or Boston, Scientific, Watertown, Mass) and/or Gelfoam (Pharmacia, Kalamazoo, Mich).

A 19-year-old back-seated male passenger was ejected from a vehicle after a crash and was sent to our emergency department (ED) for resuscitation where management followed the guidelines of *Advanced Trauma Life Support*. The patient's blood pressure was 140/80 mm Hg, and heart rate 120 beats/min on arrival. Emergent x-rays showed left zygomatic and orbital bony fracture, and a helical CT revealed severe brain contusion with swelling and grade III liver injury. However, vigorous active bleeding from the nares and oral cavity was noted. The patient initially received direct pressure tight nasal packing, which failed. Persistent hemorrhage would result in hypovolemic shock if the bleeder was not arrested; therefore, an emergent angiography via the femoral route was performed, which showed contrast extravasation of the left maxillary artery (Fig. 1A). Embolization of the left maxillary artery was performed with 2 microcoils. A follow-up external carotid artery angiogram showed that the bleeder had been embolized (Fig. 1B), and thus, no further oronasal bleeding was detected. The patient was subsequently admitted to our intensive care unit for further observation; however, on the sixth day, the patient died as a result of severe brain injury.

A 39-year-old male patient had a motorcycle accident and was sent to the ED. On arrival, the patient's blood pressure was 70/40 mm Hg, heart rate 145 beats/min; he received vigorous resuscitation and became hemodynamically stable. X-rays showed frontal bone fracture and right fourth to sixth rib fracture with a hemothorax. Helical CT revealed intracranial and subarachnoid hemorrhage and a grade III liver injury without contrast blush. After hemodynamics were stabilized, the patient was admitted to our emergency intensive care unit for further observation.

However, sudden onset of vigorous hemorrhage from the nares and oral cavity were noted on day 10, and tight packing and compression were performed but failed and persistent hemorrhage may induce hypovolemic shock. An

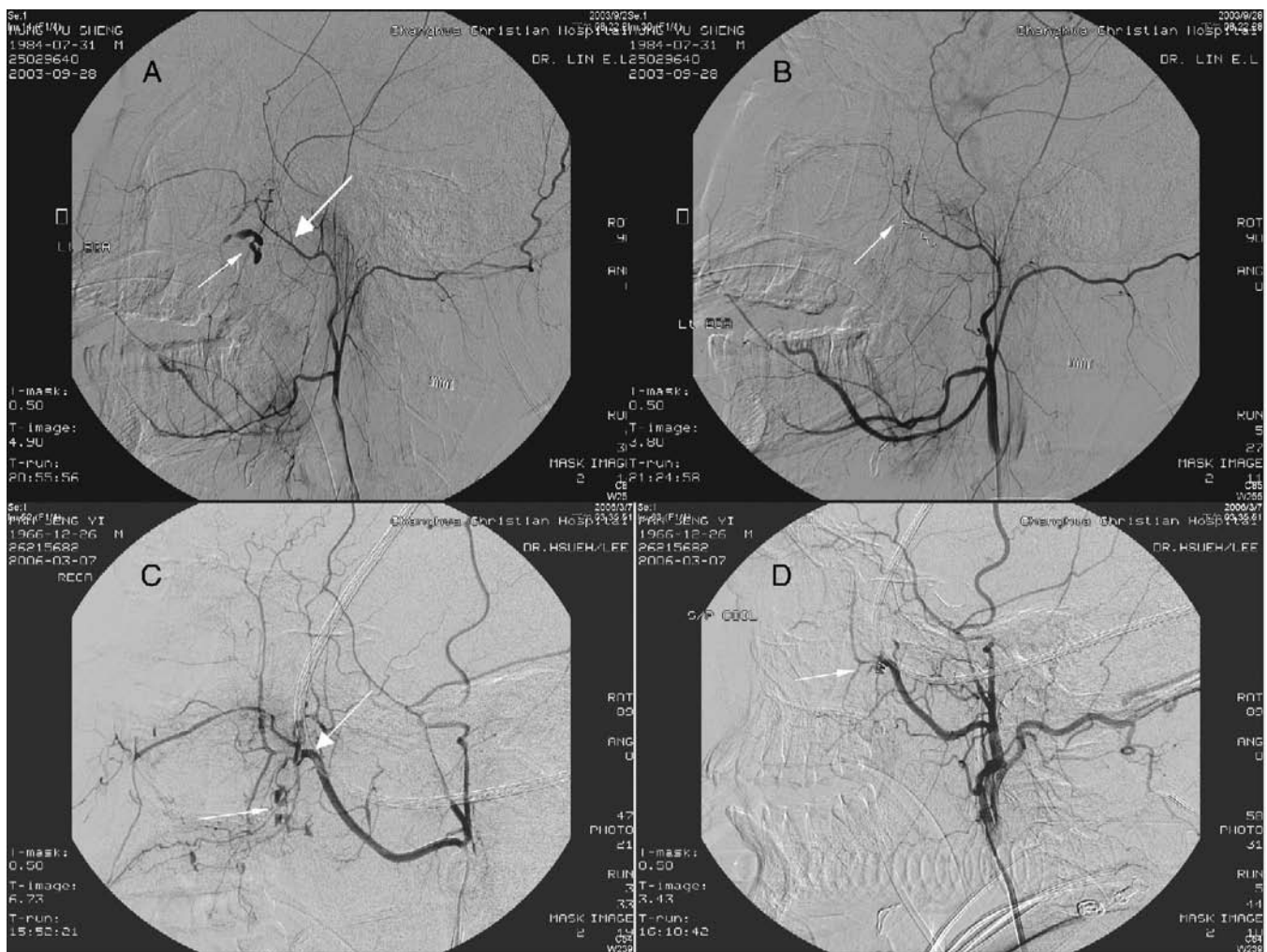


Fig. 1 A, Angiography shows left maxillary artery (large arrow) and active contrast blush (small arrow). B, No more contrast blush after coil embolization (small arrow). C, Right distal internal maxillary artery (large arrow) active contrast blush and traumatic pseudoaneurysm formation (small arrow). D, Right distal internal maxillary artery pseudoaneurysm was occluded after coil embolization (small arrow).

emergent carotid artery angiography via the femoral route showed right distal internal maxillary artery active contrast leakage and traumatic pseudoaneurysm formation (Fig. 1C). Coil embolization of the distal main trunk of the right internal maxillary artery occluded the pseudoaneurysm (Fig. 1D), and no further oronasal bleeding was detected. However, the patient underwent laparoscopic left lung wedge resection due to iatrogenic lung injury and hemorrhage after removal of the chest tube on the 20th day. The patient was discharged after careful management, and no facial numbness or tissue necrosis or other symptoms were noted during outpatient follow-up.

The characteristics of the 7 patients are listed in Table 1. The mean age of all subjects (6 males and 1 female) was 32.9 ± 14.1 years. The mean injury severity score was 41.7 ± 13.6 , and all patients had blunt injuries. Time to embolization after injury and the amount of blood transfused after embolization are shown in Table 2. The average time to embolization was 11.6 ± 7.3 hours. Four patients (57.1%) died of associated severe brain injury in

spite of arresting maxillofacial hemorrhage. Additional blood transfusions were not required after facial TAE in all patients; however, some patients received a blood transfusion due to other sources of hemorrhage (Table 2). There were 3 survivors, 1 patient (patient 2) with persistent hemorrhage after failure of tight nasal packing for 19 hours, who received successful angioembolization. The remaining 2 patients (patients 6 and 7) experienced delayed oronasal bleeding 10 and 11 days after the initial crash, and angioembolization was performed after failure of attempting hemostasis with tight nasal packing. There were no stroke, facial numbness, tissue necrosis, or other symptoms that occurred in these 3 survivors during outpatient follow-up.

Life-threatening maxillofacial trauma bleeding is not common, the incidence rate ranges from 1.2% to 4.5% in maxillofacial injuries [1-3,6], which often results in airway compromise or hypovolemia [1-3]. Management should follow the guidelines of *Advanced Trauma Life Support* with protection of the airway being the first priority [13].

Table 1 Characteristics of maxillofacial injuries

Patient	Age/Sex	Injury mechanism	Injury type			ISS	Vessel injured and embolized
			Head injuries	Lefort injury	Associated injuries		
1	19/male	Blunt (MVC)	Brain contusion	Lefort II	Liver grade III injury	35	Left maxillary artery
2	22/male	Blunt (MCC)	ICH, Skull bone fracture		Liver grade IV injury Lung injury	48	Bilateral lingual artery, perigingival branch
3	22/male	Blunt (crush)	Skull bone fracture	Lefort II		26	Right accessory maxillary artery
4	55/male	Blunt (fall)	ICH Skull bone fracture		Pelvic fracture	59	Right maxillary artery
5	26/female	Blunt (MCC)	Skull bone fracture, SAH	Lefort II	Liver grade V injury	57	Right facial artery, mandibular branch
6	39/male	Blunt (MCC)	ICH, SAH	Lefort II	Right hemothorax Liver grade III injury	50	Right distal internal maxillary artery
7	47/male	Blunt (MCC)	EDH	Lefort II		29	Right distal internal maxillary artery, sphenopalatine branch

MVC indicates motor vehicle crash; MCC, motorcycle crash; ISS, injury severity score; ICH, intracranial hemorrhage; SAH, subarachnoid hemorrhage; EDH, epidural hemorrhage.

Oronasal hemorrhage from venous origin or minor arterial vessels due to maxillofacial trauma can often be managed efficiently with manual compression or tight packing [3,6]. Some cases with serious maxillofacial trauma hemorrhage can result in hemorrhagic shock and can often require emergent open reduction and internal fixation for hemostasis [1,6]. Occasionally, complicated techniques with

ligation of focal vessels (eg, internal maxillary artery, external carotid artery) are necessary for arresting hemorrhage [7], however, this manipulation procedure could be laborious and might impinge on the stability of the cervical spine and may cause further damage.

An alternative method for controlling hemorrhage is TAE [3,11,12,14], which has been widely used in severe non-

Table 2 Time to embolization after injury and amount of blood transfused post procedure

Patient no.	Time to TAE after injury or delayed bleeding (h)	BT before TAE (mL)	BT after TAE (mL)	Local effect	Systemic effect and outcome
1	17.7	2000	0	No more nasal bleeding after facial TAE	Die of brain injury
2	19.2	1500	500	No further nasal bleeding after facial TAE	Delayed liver hemorrhage on the 12th day, received BT and liver TAE Survived
3	5.8	2000	250	No further nasal bleeding after facial TAE	Died of brain injury
4	4.0	1500	2000	No further nasal bleeding after facial TAE	Died of brain injury
5	2.0	1000	12,000	No further nasal bleeding after facial TAE	Associated pelvic fracture with bleeding, received BT and pelvic TAE Died of brain injury and severe liver injury
6	17.0	5500	0	No further nasal bleeding after facial TAE Small groin hematoma	Induced hemorrhagic shock Iatrogenic lung injury and bleeding on the 20th day after removing chest tube, received laparoscopic thoractomy, BT 1500 mL Survived
7	15.2	1500	0	No further nasal bleeding after facial TAE	Survived

BT indicates blood transfusion.

traumatic epistaxis for many years [9,10]. Although the wide application of TAE in traumatic torso or intra-abdominal solid organ hemorrhage or pelvic fracture had been reported [15], knowledge of TAE usage for maxillofacial hemorrhage was mostly gained from otolaryngology literature concerning patients with severe epistaxis [8-10]. However, TAE has been recently reported as the primary choice for life-threatening maxillofacial trauma bleeding [2,3,11,12].

In this series, 7 patients experienced life-threatening maxillofacial trauma hemorrhage and received TAE; no further nasal bleeding were detected after the procedure. Additional blood transfusions were necessary in 4 patients due to other sources of hemorrhage (Table 2). Four patients died of brain injuries. No facial numbness, tissue necrosis, or other symptoms were detected in the 3 survivors during outpatient follow-up. Arresting nasal hemorrhage shows that TAE may serve as an efficient alternative for hemostasis in life-threatening maxillofacial hemorrhage.

Associated cerebral trauma and severe brain injuries are common in maxillofacial trauma. To our knowledge, persistent maxillofacial hemorrhage might result in brain hypoperfusion as well as secondary brain injuries, which often result in adverse outcomes [16,17]. However, it has been reported that early treatment of cerebral hypoperfusion status may reduce secondary brain injury and decrease mortality [18]. We believe that in cases where failure of tight packing occurs, early hemostasis for maxillofacial hemorrhage with TAE might be helpful in shortening the hypoperfusion status and preventing the brain from further damage.

Additional blood transfusions were not required after facial TAE in all patients; however, some patients received a blood transfusion due to other sources of hemorrhage (Table 2). The decreased amount of blood transfusion was inclined to reduce the possibilities of blood-borne diseases [19].

In our series, there were no stroke, facial numbness, tissue necrosis, or other symptoms that occurred in the 3 survivors. Although angioembolization is quite safe for hemorrhage from branches of external carotid artery, it is not without hazard when embolizing internal maxillary artery. The possibilities of embolus migrating into the brain and causing cerebrovascular accident or stroke should be noted. However, the reported risk of dislodging the embolizing agent is about 1.9% in experienced hands [20].

The oronasal status of patients 6 and 7 were normal initially; however, both patients experienced delayed oronasal bleeding 10 and 11 days after the initial crash. Tight packing of the nares was performed but failed; thus, embolization was performed within 24 hours, and the bleeding was stopped. Although the exact reason for the delayed hemorrhage is unclear, as we know, a higher injury severity score often predicts nonoperative management failure in blunt splenic injuries [21], it is to be elucidated whether a higher injury severity score is of predictive value in delayed maxillofacial hemorrhage. On the other hand, there were organized thrombus and blood clots after vessel injuries in

normal subjects [22,23]. In this series, both patients were with severe head and brain injuries (head abbreviated injury score = 5) (Table 1) and were under bedridden resting state within the first week of hospital stay. It is of interest whether regaining activities after recovery might result in breakdown of the stabilized blood clots and induce delayed hemorrhage. However, possibilities of delayed life-threatening hemorrhage after maxillofacial trauma should be considered.

Life-threatening maxillofacial trauma hemorrhage is not common; the oronasal hemorrhage from maxillofacial trauma can often be managed with manual compression or efficient tight packing. Emergency surgery is reserved for cases where failure of tight packing occurs. In this series, TAE decreases the need for blood transfusion and provides an effective alternative for early hemostasis after packing failure, which might shorten hypoperfusion status and prevent secondary brain injury. However, the possibilities of delayed life-threatening maxillofacial hemorrhage have to be considered, and we suggest transarterial embolization to be considered as the primary choice of treatment. Further prospective studies elucidating the role of early transarterial embolization in life-threatening maxillofacial trauma hemorrhage and determining the relationship between higher injury severity score and delayed maxillofacial hemorrhage are necessary.

Shih-Chi Wu

Division of Trauma

Changhua Christian Hospital

Changhua 500, Taiwan, ROC

Trauma and Emergency Center

China Medical University Hospital

Taichung 404, Taiwan, ROC

E-mail address: rw114@www.cmuh.org.tw

Ray-Jade Chen

Trauma and Emergency Center

China Medical University Hospital

Taichung 404, Taiwan, ROC

E-mail address: rayjchen@www.cmuh.org.tw

Kwo-Whei Lee

Division of Radiology

Changhua Christian Hospital

Changhua 500, Taiwan, ROC

E-mail address: 94692@cch.org.tw

Cheng-Cheng Tung

Wen-Pei Lin

Poon Yi

Division of Trauma

Changhua Christian Hospital

Changhua 500, Taiwan, ROC

E-mail addresses: 111233@cch.org.tw

bv6jc@yahoo.com.tw, 104080@cch.org.tw

References

- [1] Tung TC, Tseng WS, Chen CT, et al. Acute life-threatening injuries in facial fracture patients: a review of 1025 patients. *J Trauma* 2000; 49(3):420-4.
- [2] Yang WG, Tsai TR, Hung CC, et al. Life-threatening bleeding in facial fracture. *Ann Plast Surg* 2001;46(2):159-62.
- [3] Bynoe RP, Kerwin AJ, Parker III HH, et al. Maxillofacial injuries and life-threatening hemorrhage: treatment with transcatheter arterial embolization. *J Trauma* 2003;55(1):74-9.
- [4] Brookes C, Wang S, McWilliams J. Maxillofacial injuries in North American vehicle crashes. *Eur J Emerg Med* 2003;10(1):30-4.
- [5] Murphy Jr RX, Birmingham KL, Okunski WJ, et al. The influence of airbag and restraining devices on the patterns of facial trauma in motor vehicle collisions. *Plast Reconstr Surg* 2000;105(2):516-20.
- [6] Ardekian L, Samet N, Shoshani Y, et al. Life-threatening bleeding following maxillofacial trauma. *J Craniomaxillofac Surg* 1993;21(8): 336-8.
- [7] Cullen MM, Tami TA. Comparison of internal maxillary artery ligation versus embolization for refractory posterior epistaxis. *Otolaryngol Head Neck Surg* 1998;118(5):636-42.
- [8] Christensen NP, Smith DS, Barnwell SL, et al. Arterial embolization in the management of posterior epistaxis. *Otolaryngol Head Neck Surg* 2005;133(5):748-53.
- [9] Ricci G, Molini E, Hamam M, et al. Treatment of severe epistaxis by superselective embolization: a review of 22 cases. *Rev Laryngol Otol Rhinol (Bord)* 2004;125(4):247-51.
- [10] Nickel J, Sachs W, Andresen R. Selective embolisation of posttraumatic intractable epistaxis. *Rontgenpraxis* 2003;55(2):72-7.
- [11] Baqain ZH, Thakkar C, Kalavrezos N. Superselective embolization for control of facial haemorrhage. *Injury* 2004;35(4):435-8.
- [12] Siritongtaworn P. Management of life-threatening hemorrhage from facial fracture. *J Med Assoc Thai* 2005;88(3):382-5.
- [13] American College of Surgeons, Committee on Trauma. Advanced trauma life support manual. 7th ed. Chicago (Ill): American College of Surgeons; 2004.
- [14] Murakami R, Kumazaki T, Tajima H, et al. Transcatheter arterial embolization as treatment for life-threatening maxillofacial injury. *Radiat Med* 1996;14(4):197-9.
- [15] Velmahos GC, Toutouzas KG, Vassiliu P, et al. A prospective study on the safety and efficacy of angiographic embolization for pelvic fracture and visceral injuries. *J Trauma* 2002;53(2): 303-8.
- [16] Hlatky R, Contant CF, Diaz-Marchan P, et al. Significance of a reduced cerebral blood flow during the first 12 hours after traumatic brain injury. *Neurocrit Care* 2004;1(1):69-83.
- [17] Jeremitsky E, Omert L, Dunham CM, et al. Harbingers of poor outcome the day after severe brain injury: hypothermia, hypoxia, and hypoperfusion. *J Trauma* 2003;54(2):312-9.
- [18] Ghajar J. Traumatic brain injury. *Lancet* 2000;356(9233):923-9.
- [19] Chamberland ME. Surveillance for bloodborne infections. *Thromb Haemost* 1999;82(2):494-9.
- [20] Remonda L, Schroth G, Caversaccio M, et al. Endovascular treatment of acute and subacute hemorrhage in the head and neck. *Arch Otolaryngol Head Neck Surg* 2000;126(10):1255-62.
- [21] McIntyre LK, Schiff M, Jurkovich GJ. Failure of nonoperative management of splenic injuries: cause and consequences. *Arch Surg* 2005;140(6):563-8.
- [22] Jurk K, Kehrel BE. Platelets: physiology and biochemistry. *Semin Thromb Hemost* 2005;31(4):381-92.
- [23] Stassen JM, Arnout J, Deckmyn H. The hemostatic system. *Curr Med Chem* 2004;11(17):2245-60.